

Pulmonary changes in cardiac patients: comparison with other pulmonary diseases

October 30, 2011 CWVS symposium
Dr A. Mareschal, DVM, DACVR
Pan Pacific Hotel

Introduction

- Thoracic Rads: routine cardiac workup
- Pulmonary changes, only in left sided CHF
- Similar Rx features with other pulmonary diseases?

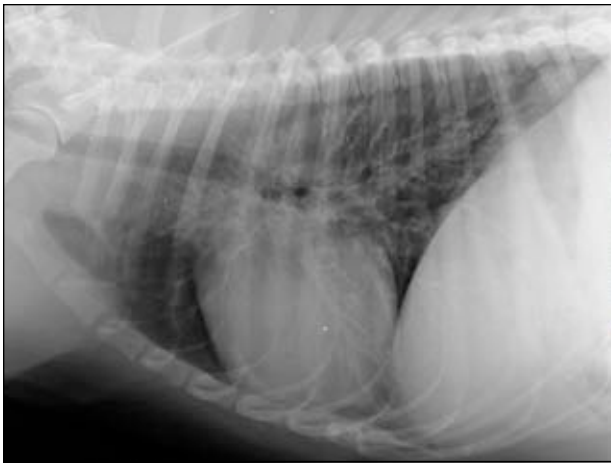Pulmonary parenchyma description


- Lung opacity
- Distribution of the lesion(s)
- Appearance of pulmonary changes
- Lung lobe size



Pulmonary patterns: Bronchial


- Increased bronchial wall thickening
 - "Doughnuts"
 - "Tram lines"
- ≠ Bronchial wall mineralization
- For recognition:
 - Check periphery
 - Check 2 orthogonal views
 - Check subcutaneous tissue for doughnuts!!




 CANADA WEST
VETERINARY SPECIALISTS

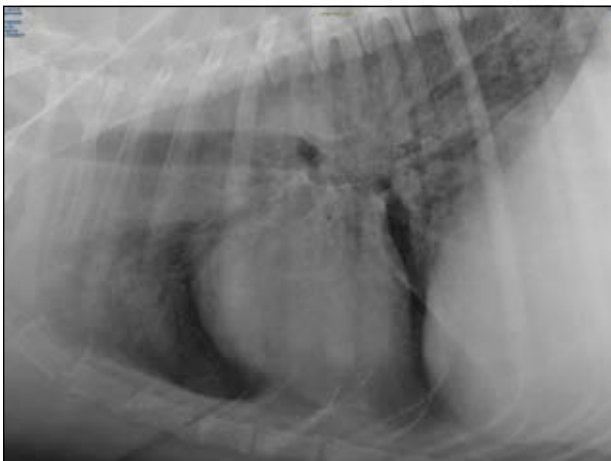
Pulmonary patterns: Interstitial

- Increased pulmonary opacity
- Ill-defined pulmonary vessel margins
- Peribronchial = early interstitial

 CANADA WEST
VETERINARY SPECIALISTS

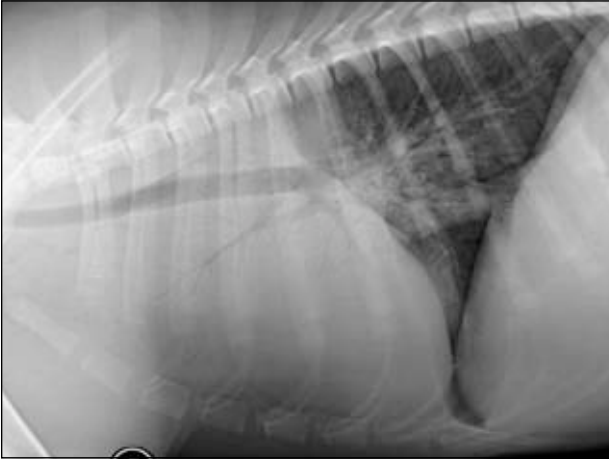


Bronchial Normal (Peribronchial)




Pulmonary patterns: Alveolar

- Marked increased in soft tissue opacity
- Non-visible pulmonary vessels
- Air bronchograms
- Lobar sign



Radiographic Patterns

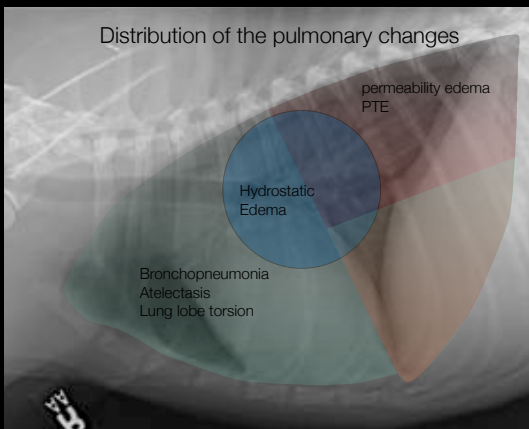
Normal



Interstitial

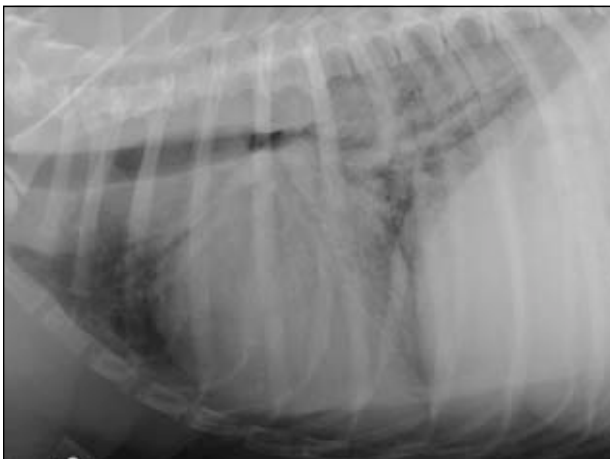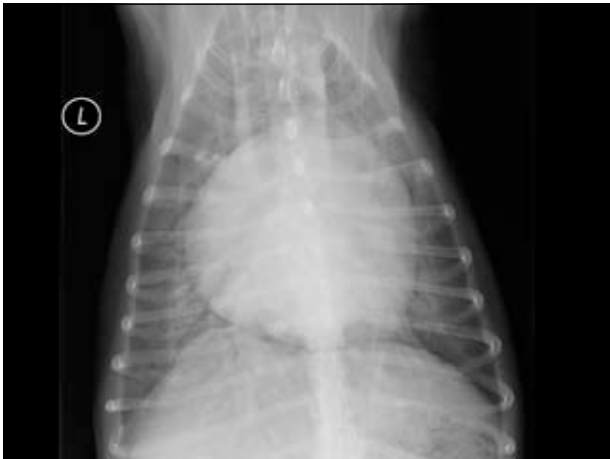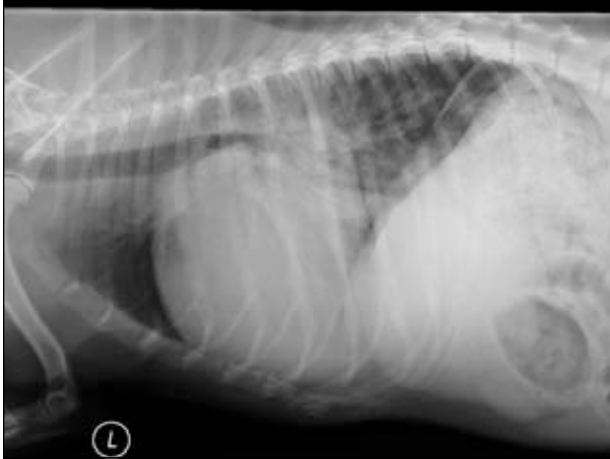Alveolar

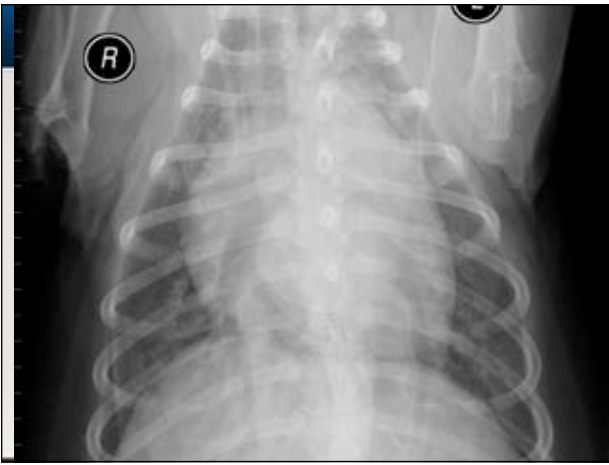Distribution of the pulmonary changes




Radiographic features of LCHF in dogs

- Perihilar to caudodorsal interstitial then alveolar pattern
- Pulmonary vascular distension
- Left sided cardiomegaly
- Left atrial enlargement
- Possible aerophagia

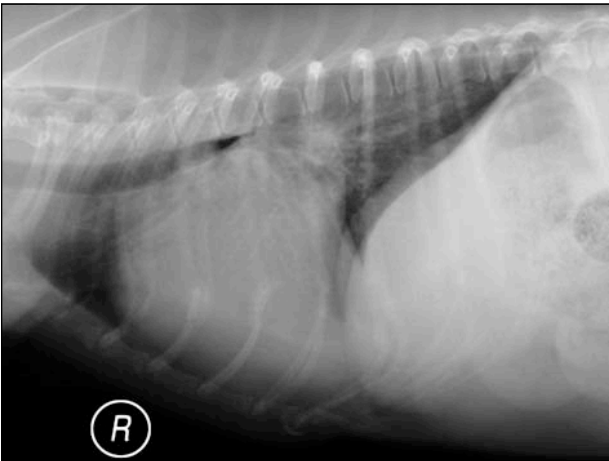





 CANADA WEST
VETERINARY SPECIALISTS

Pitfalls

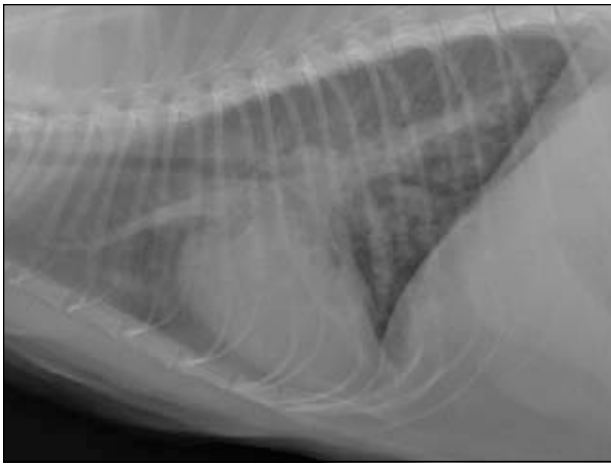
- Perihilar pulmonary changes \neq Left atrial enlargement
- Edema may change distribution
- Normal pulmonary vessels \neq Non-cardiogenic edema
- Normal cardiac silhouette

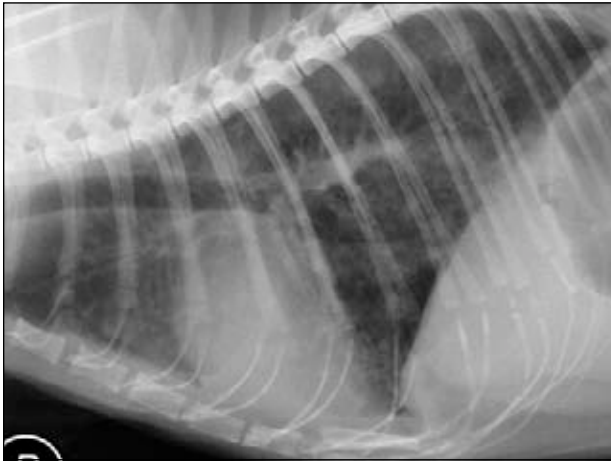


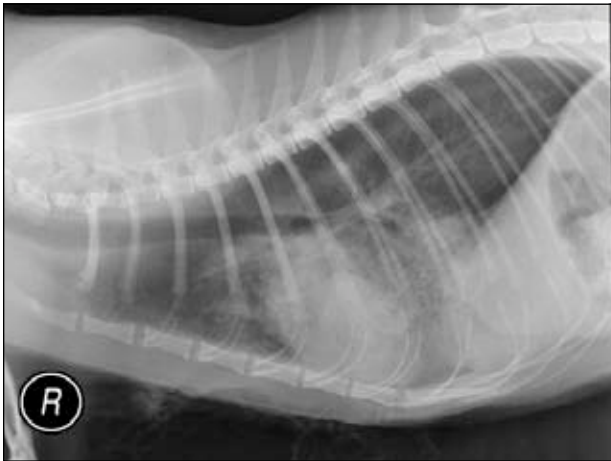 CANADA WEST
VETERINARY SPECIALISTS

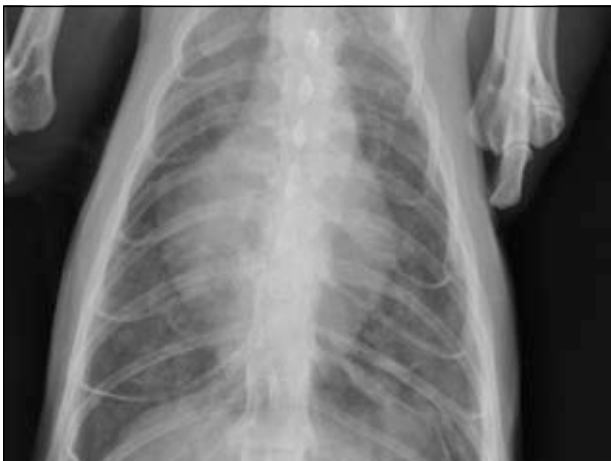LCHF in feline patient

- More challenging diagnosis on Rads
- **Patchy** interstitial pattern
- Valentine shape on VD
- Pulmonary vessel enlargement
- Pleural effusion



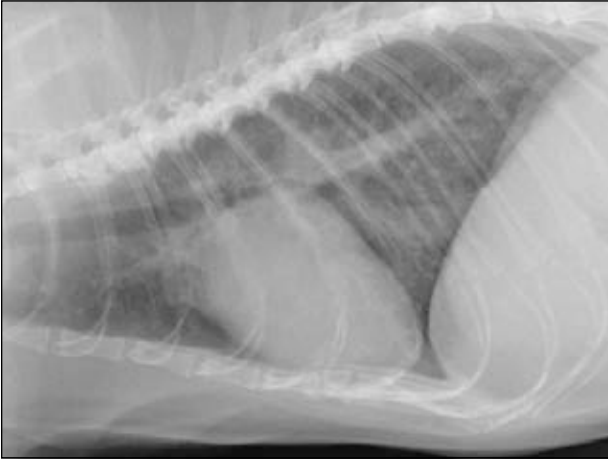

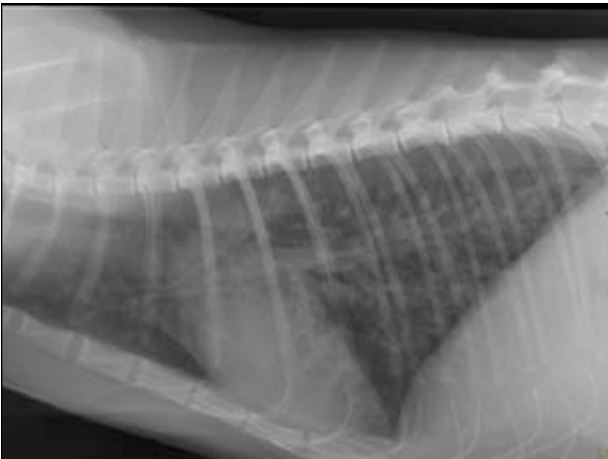




Pitfalls

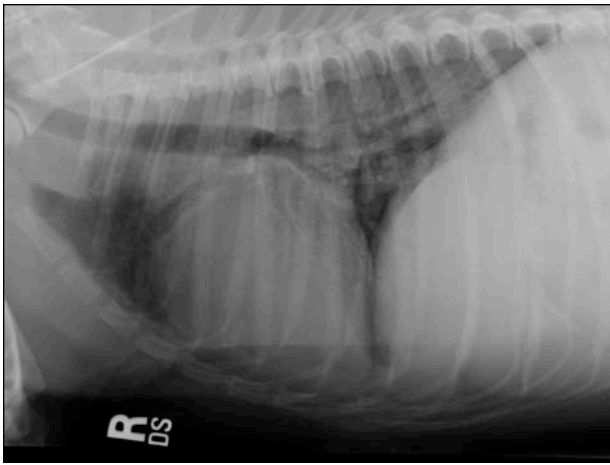
- Confusion between peribronchial and bronchial pattern
- Cardiomegaly more difficult to assess

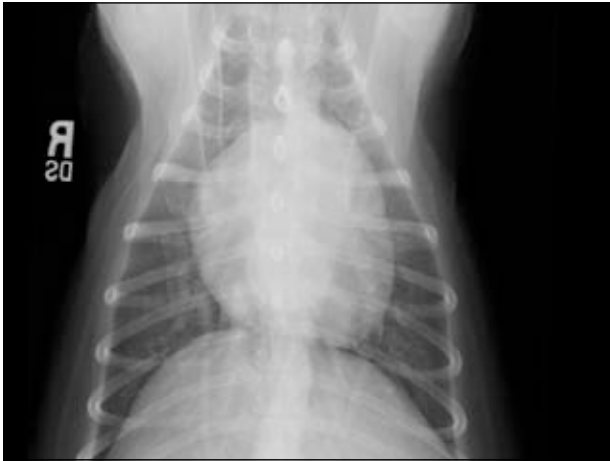




Follow-up of cardiac patient

- Response to diuretic within few hours
 1. Quick reduction of the pulmonary vasculature diameter
 2. Quick reduction of pulmonary edema





CANADA WEST
VETERINARY SPECIALISTS

LCHF: Differential diagnosis

Dogs	<ul style="list-style-type: none"> ✦ Non-cardiogenic edema ✦ Volume overload ✦ Neoplasia (LSA) 	<ul style="list-style-type: none"> ✦ PIE/EBP
	Cats	<ul style="list-style-type: none"> ✦ Hemorrhage ✦ PTE

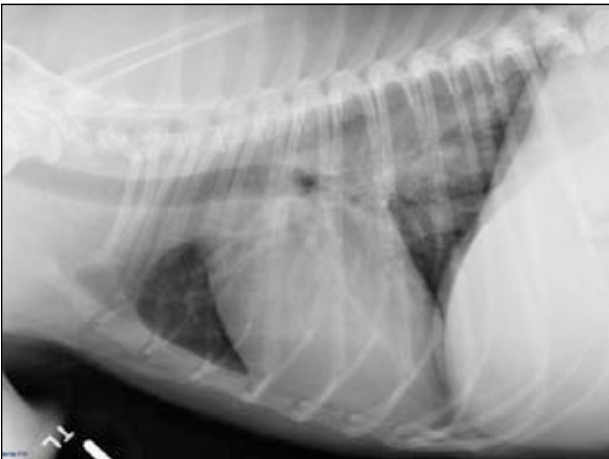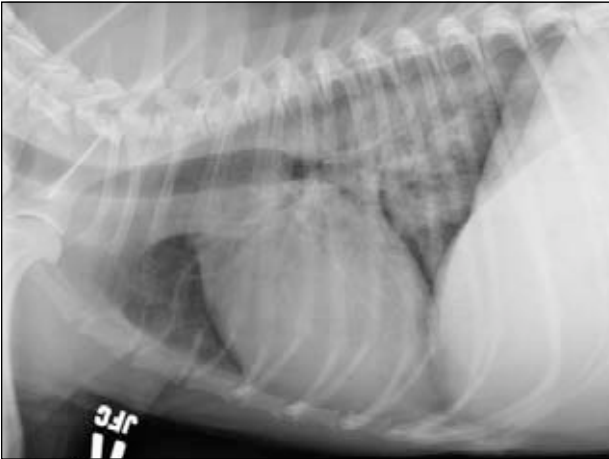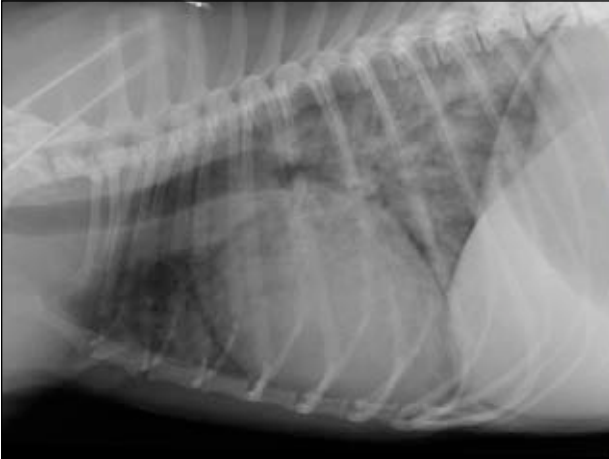
CANADA WEST
VETERINARY SPECIALISTS

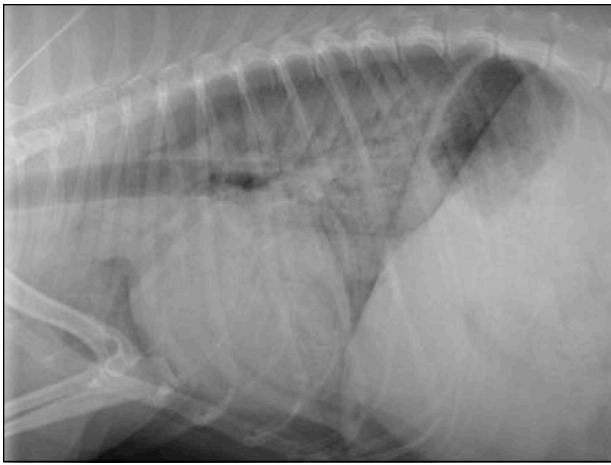
Non-Cardiogenic Edema

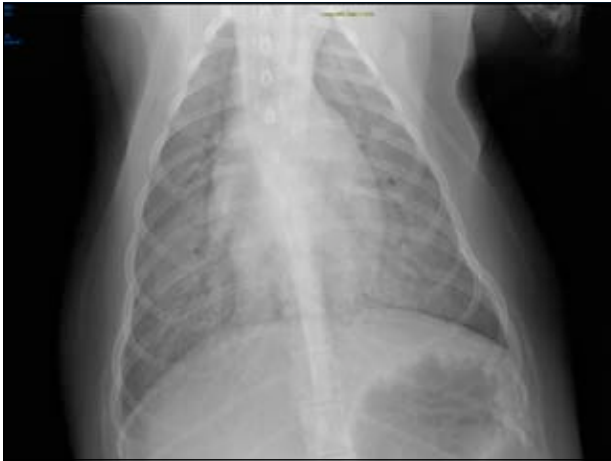- Neurogenic edema
- Upper airway obstruction
- Permeability edema
 - ARDS, SIRS, DIC, vasculitis, pancreatitis
 - Immune mediated lung disease
 - Anaphylactic reaction
 - uremic pneumonitis, sepsis (lepto)
- Near drowning

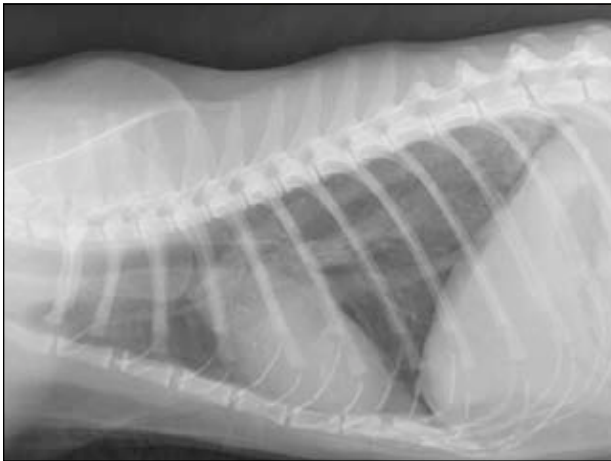
Features of Non-Cardiogenic Edema

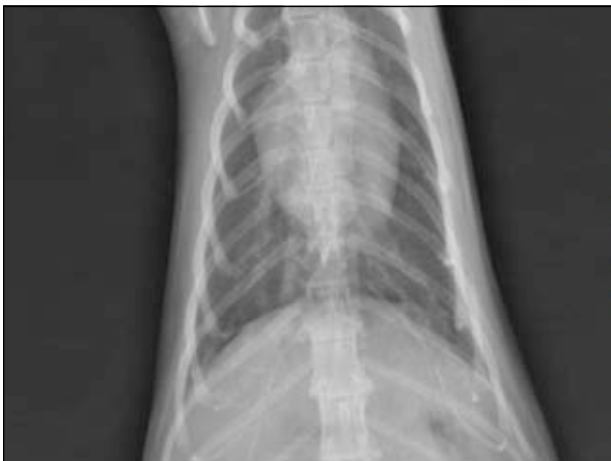	Dogs	Cats
Similar to LCHF	<ul style="list-style-type: none"> † Unstructured interstitial to alveolar † Aerophagia 	<ul style="list-style-type: none"> † Pleural effusion
Different from LCHF	<ul style="list-style-type: none"> † Normal cardiovascular structures † Pleural effusion † ~Asymmetric 	<ul style="list-style-type: none"> † Caudo-dorsally distributed





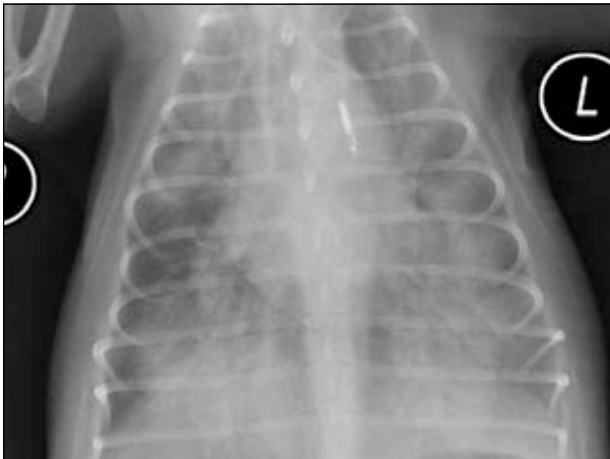
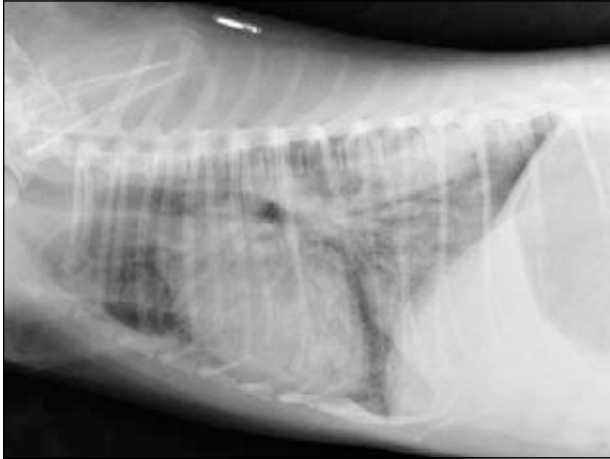




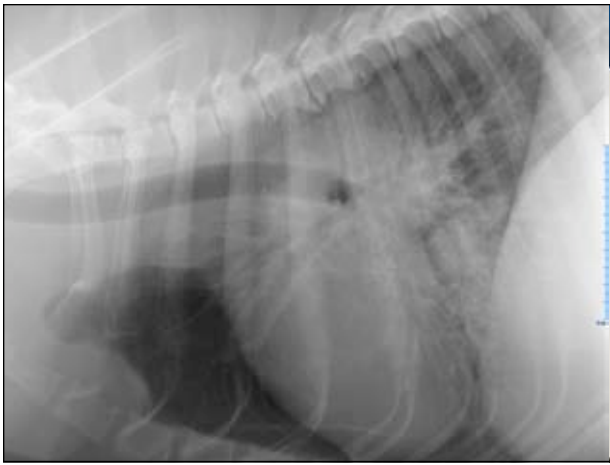
Volume Overload

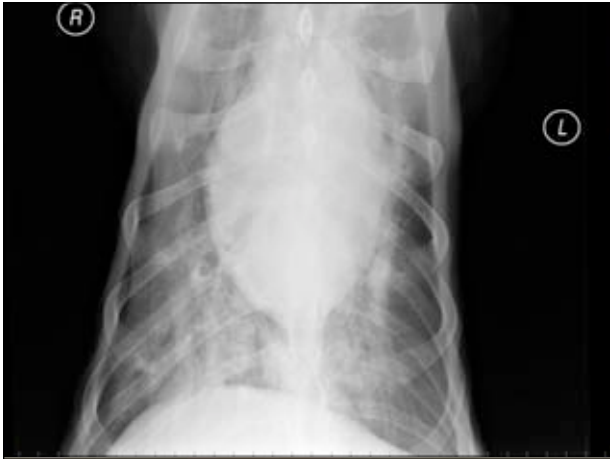	Dogs	Cats
Similar to LCHF	<ul style="list-style-type: none"> Unstructured interstitial to alveolar Enlarged pulmonary vessels 	<ul style="list-style-type: none"> Patchy edema Pleural effusion Normal to mild cardiomegaly
Different from LCHF	<ul style="list-style-type: none"> Pleural effusion Normal cardiac silhouette 	<ul style="list-style-type: none"> Not so much...



Pulmonary Lymphoma

- Similar features to LCHF
 - Increased perihilar opacity (TB LN)
 - Interstitial to alveolar pattern
- How to differentiate from LCHF
 - Random distribution of the pulmonary changes
 - Possible pleural effusion
 - Often sternal lymph nodes

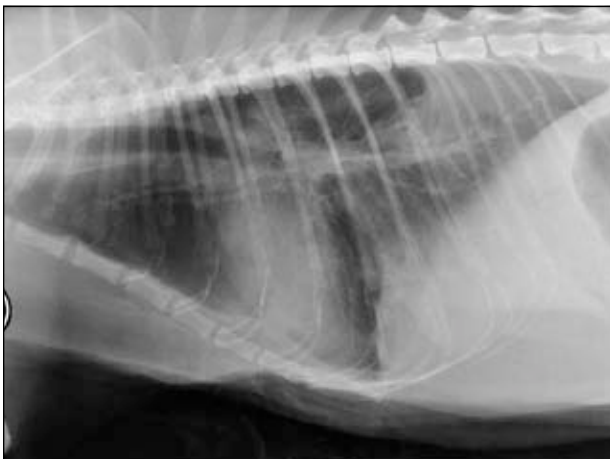


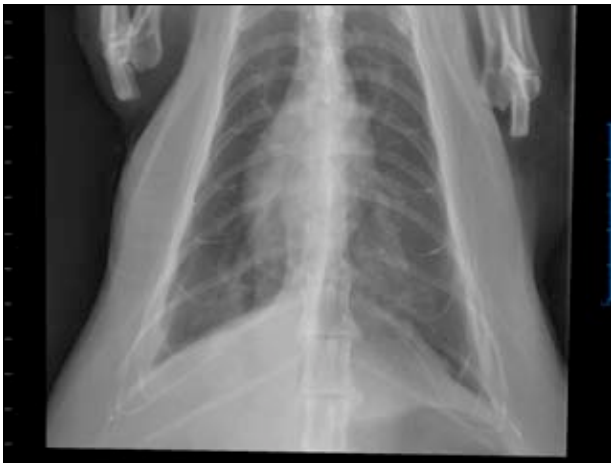

CANADA WEST
VETERINARY SPECIALISTS

Pulmonary Thromboembolism

	Dogs	Cats
Similar to LCHF	<ul style="list-style-type: none"> Unstructured interstitial to alveolar Possible pulmonary enlargement 	<ul style="list-style-type: none"> Patchy Asymmetric
Different from LCHF	<ul style="list-style-type: none"> Normal cardiovascular structures Very Focal Asymmetric 	<ul style="list-style-type: none"> N/A






 CANADA WEST
VETERINARY SPECIALISTS

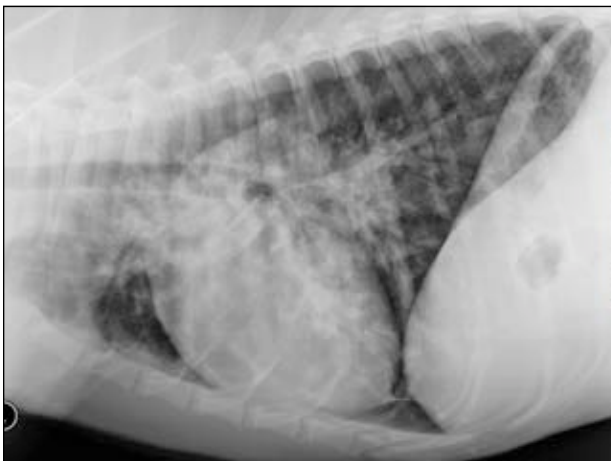Pulmonary hemorrhage

- Similar features to LCHF
 - Unstructured interstitial to alveolar pattern
- How to differentiate from LCHF
 - Random distribution
 - Possible mediastinal or pleural hemorrhage
 - Possible tracheal narrowing

 CANADA WEST
VETERINARY SPECIALISTS

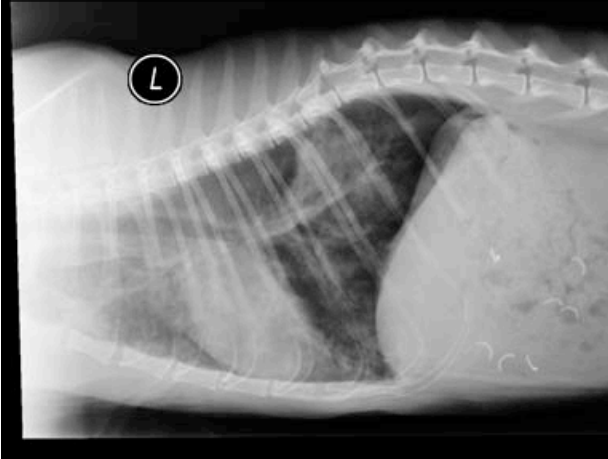
Canine Eosinophilic bronchopneumopathy

- Similar features to LCHF
 - Unstructured interstitial to alveolar pattern
- How to differentiate from LCHF
 - **Normal cardiovascular structures**
 - **Asymmetric**
 - **Nodules/masses** possible
 - **Often bronchial** component
 - Possible bronchiectasis



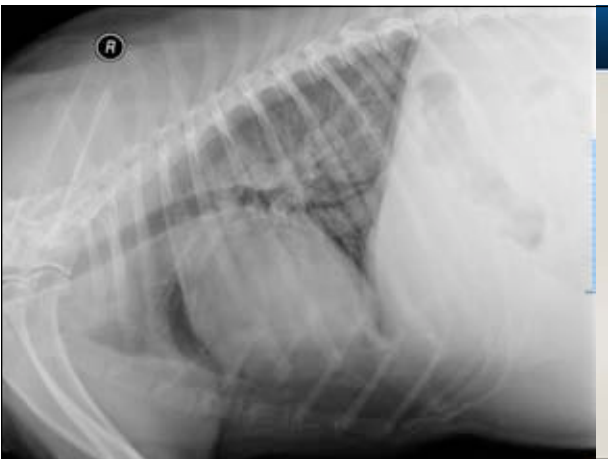Feline infectious, allergic and parasitic pulmonary diseases

- Similar features to LCHF
 - Multifocal unstructured interstitial to alveolar pattern
- How to differentiate from LCHF
 - **Bronchial pattern predominates!!**
 - Normal cardiovascular structures
 - **Nodules** possible



Right sided heart Failure

- No pulmonary changes
- Right sided cardiomegaly
- Pleural effusion
- Enlarged Caudal Vena cava
- Abdominal effusion, hepatosplenomegaly



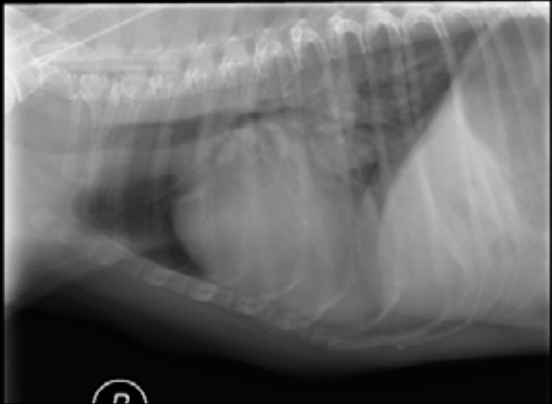Radiographic quality: Maximize your chances...

- Bad radiographs lead to erroneous interpretation
 - Sedation
 - Positioning
 - Exposure
 - Collimation
- Avoid digital compression.

Conclusion

- Quality rads and systematic approach
- Clinical history and cardiovascular structures within normal limits.
- Several disease processes happening at the same time?

When it's hard to decide...



Questions?